

Atherosclerosis and myocardial bridging: Not a benign combination. An autopsy case report

M. J. Thej, R. Kalyani, J. Kiran¹

Departments of Pathology and ¹Forensic Medicine, Sri Devaraj Urs Medical College, Sri Devaraj Urs Academy of Higher Education and Research, Kolar, Karnataka, India

Address for correspondence: Dr. R. Kalyani, Professor of Pathology, Sri Devaraj Urs Medical College, Sri Devaraj Academy of Higher Education and Research, Kolar - 563 101, Karnataka, India.

E-mail: drkalyanir@rediffmail.com

ABSTRACT

Myocardial bridging is a congenital coronary anomaly with a variety of clinical manifestations. Traditionally, myocardial bridging has been considered a benign condition, but some cases of myocardial ischemia, infarction and sudden cardiac death due to myocardial bridging have been reported. Various studies have suggested that in their intramyocardial segments, these vessels are protected from obstructive atherosclerosis, with atherosclerosis being present in the proximal part of the artery. We report a case in a 45-year-old male who had a 2.5-cm long myocardial bridging over the left anterior descending artery, with obstructive atherosclerosis being present in the proximal as well as the intramyocardial part (part of the artery below the myocardial bridge). Atherosclerosis occurring in the intramyocardial segment is a rare occurrence, and combined with systolic narrowing by the myocardial bridge can lead to ischemia of the cardiac musculature.

Key words: Heart, myocardium, myocardial bridging

INTRODUCTION

Myocardial bridging is defined as a segment of the major coronary artery running intramurally through the myocardium, deviating from its usual epicardial course.^[1-3] Myocardial bridging is most commonly seen in the left coronary artery distribution.^[4] The clinical significance of this common congenital condition of the coronary arteries is controversial, with some believing it to be completely benign while others attach a pathological tag to myocardial bridges. Reports of various cardiac complications occurring with myocardial bridges are present.^[1] Although myocardial bridges are a relatively

common congenital condition, it has been believed that the intramyocardial segment of the coronary artery is protected from atherosclerosis compared to the proximal portion of the artery due to variable shear forces of blood flow.^[1,3] Herein, we report an unusual case with a combination of myocardial bridging over the left anterior descending artery with obstructive atherosclerosis in the intramyocardial part.

CASE REPORT

Autopsy was conducted on a 45-year-old male patient who had suddenly collapsed while at work and died before any medical help could arrive. He worked as a manual laborer where his work required strenuous effort. He was moderately built and his height was 173 cms. He was a known smoker, occasional alcoholic, meat eater and tobacco chewer. No history of hypertension, diabetes or other disorders was available. At autopsy, dissection of the coronary arteries in the heart showed a 2.5-cm (25 mm) long myocardial bridge present over the left anterior descending artery [Figures 1 and 2]. Gross examination

Access this article online	
Quick Response Code: 	Website: www.jcdronline.com
	DOI: 10.4103/0975-3583.95380

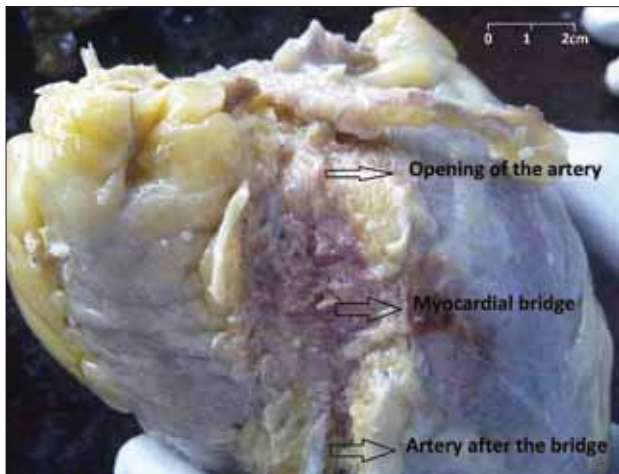


Figure 1: Gross photograph showing myocardial bridge over the left anterior descending artery

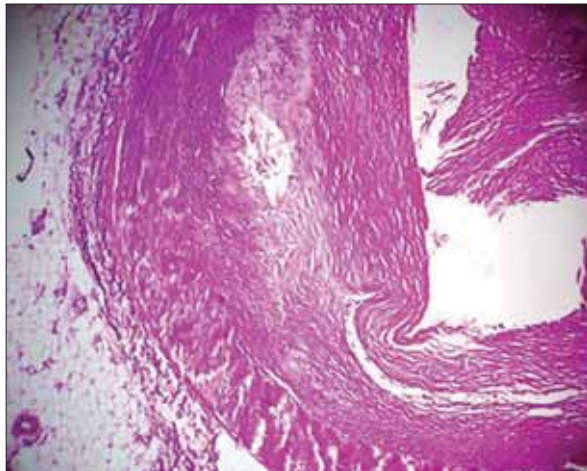


Figure 3: Microphotograph showing fibrous cap atheroma with cardiac muscle covering the adventitia of the artery (H and E x100)

of the coronaries and aorta showed presence of atherosclerosis in most parts of the arteries. Atherosclerosis was also present in the intramyocardial segment of the left anterior descending artery as well as in the part proximal to it. Microscopic examination revealed thick fibrous cap atheroma being present in the intramyocardial segment, causing significant occlusion [Figure 3]. None of the atheromatous lesions in the coronary artery showed rupture or thrombus formation. Aorta showed atheromatous lesions without any complications. Myocardium supplied by the left anterior descending artery beyond the myocardial bridge showed early changes of infarction such as waviness of fibers and a few neutrophils.

DISCUSSION

Myocardial bridging was first described by Reyman in 1737 at autopsy, and since then it has been the topic of much debate regarding its clinical significance.^[1] It has been

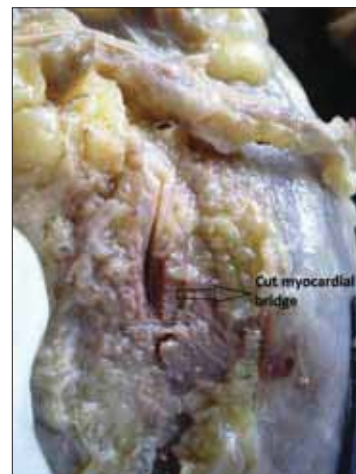


Figure 2: Gross photograph showing cut myocardial bridge over the left anterior descending artery

given various names like “myocardial bridge,” “intramural coronary artery,” “mural coronary artery,” “coronary artery overbridging” and “myocardial loop.”^[5] The first angiographic description of myocardial bridge *in vivo* was given by Porstmann and Iwig in 1960.^[5] The incidence of myocardial bridges has been reported to vary between 15 and 85% at autopsy and 1.5 and 16% in angiographic series.^[1] This discrepancy might be due to the difficulty of picking up the systolic narrowing in angiography and also due to the inclusion of epicardial artery loops with myocardial bridging in autopsy series.^[2,4]

Major part of the blood flow to the cardiac musculature occurs during the diastolic phase. The myocardial bridge causes coronary artery narrowing during systole and therefore technically speaking, myocardial bridges should not compromise blood supply to the musculature during diastole.^[5] Various complications like ischemia and acute coronary syndromes, coronary spasm, arrhythmias, exercise-induced atrioventricular conduction block, cardiac stunning and sudden death are known to occur due to myocardial bridging.^[1-3,6,7] The study by Bourassa *et al.*, states that milking effect of the myocardial bridge on the coronary artery extends from systole into diastole, leading to delay in early diastolic diameter gain and also mid-diastolic diameter reduction.^[8] The reduction in the diameter of the coronary artery during diastole can have clinical effects like ischemia when the patient has a rapid heart rate where the diastolic phase is relatively shortened, leading to decreased blood supply to the musculature.^[5] One of the hypothesis states that the systolic kinking may lead to trauma to the endothelial cells and starting off platelet aggregation and vasospasm, resulting in an acute coronary syndrome.^[1] Our case did not show thrombus formation or rupture of the atherosclerotic plaque. Hence, coronary vasospasm of the

atherosclerosed arterial segment possibly could have led to the myocardial ischemia and death, as no other cause for sudden death in the patient could be found. Atherosclerosis combined with vasospasm leads to decreased blood supply during diastole. The musculature deriving blood supply from the affected artery showed early changes of myocardial infarction in our case.

The degree of the obstruction caused by the myocardial bridge depends on factors such as location, thickness and length of the muscle bridge.^[1] Studies have shown that the intima of the intramyocardial segment is significantly thinner than the proximal segment and that it could be protected by pro-atherosclerotic factors such as shear stress.^[1] Histologic studies have shown that the intramyocardial segment consists only of contractile type smooth muscle cells and lacks synthetic type of smooth muscle, explaining the absence of atherosclerosis.^[1] Ge *et al.*, studied 14 cases of which 86% had atherosclerotic lesions, but all of these were located proximal to the bridged segment with no atherosclerotic lesions in the intramyocardial segment.^[9] A few case reports of atherosclerosis occurring in the intramyocardial segment like the one by Winter RJE *et al.*, show that it can occur and can have adverse clinical effects.^[3]

CONCLUSION

Myocardial bridging is a commonly found, mostly benign, anatomic variation found at autopsy or angiographic evaluation. Myocardial bridging should be kept in mind as a differential diagnosis in patients who have angina but do not have the traditional risk factors or in those

patients where the angina is induced by strenuous exercise. As seen in this case, atherosclerosis can occur in the intramyocardial segment of the artery, and this fact should be kept in mind for the effective treatment of the patient. Careful angiographic screening for atherosclerosis in the intramyocardial segment should be conducted. Myocardial bridges might not be as benign as they are thought to be.

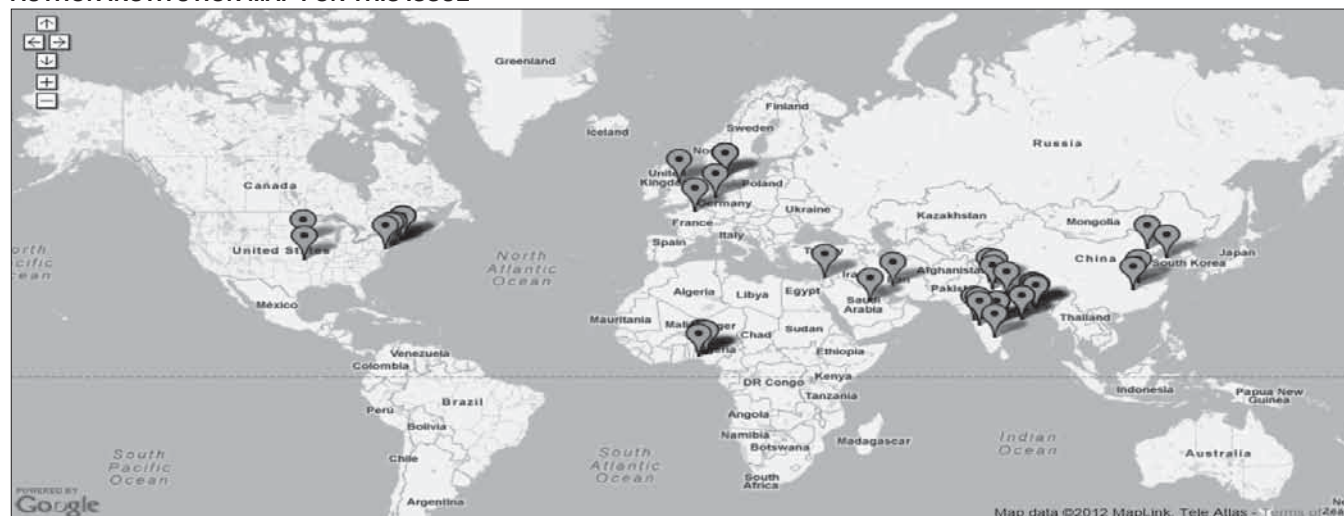REFERENCES

1. Alegria JR, Herrmann J, Holmes Jr DR, Lerman A, Rihal CS. Myocardial bridging. *Eur Heart J* 2005;26:1159-68.
2. Soran O, Pamir G, Erol C, Kocakavak C, Sabah I. The incidence and significance of myocardial bridge in a prospectively defined population of patients undergoing coronary angiography for chest pain. *Tokai J Exp Clin Med* 2000;25:57-60.
3. Winter RJ, Kok WE, Piek JJ. Coronary atherosclerosis within a myocardial bridge, not a benign condition. *Heart* 1998;80:91-3.
4. Nguyen TH, Burnside PR, Dieter RS, Nanjundappa A. Right coronary artery distribution of myocardial bridging. An unusual case presenting with ST-elevation myocardial infarction. *Tex Heart Inst J* 2007;34:489-491.
5. Hayashi T, Ishikawa K. Myocardial bridge: Harmless or harmful. *Int Med* 2004;43:1097-8.
6. Venkateshu KV, Mysorekar VR, Sanikop MB. Myocardial Bridges. *J Indian Med Assoc* 2000;98:691-3.
7. Akdemir R, Gunduz H, Emiroglu Y, Uyan C. Myocardial bridging as a cause of acute myocardial infarction: A case report. *BMC Cardiovasc Disord* 2002;2:15.
8. Bourassa MG, Butnaru A, Lesperance J, Tardif JC. Symptomatic myocardial bridges: Overview of ischemic mechanisms and current diagnostic and treatment strategies. *J Am Coll Cardiol* 2003;41:351-9.
9. Ge J, Erbel R, Gorge G, Haude M, Meyer J. Comparison of intravascular ultrasound and angiography in the assessment of myocardial bridging. *Circulation* 1994;89:1725-32.

How to cite this article: Thej MJ, Kalyani R, Kiran J. Atherosclerosis and myocardial bridging: Not a benign combination. An autopsy case report. *J Cardiovasc Dis Res* 2012;3:176-8.

Source of Support: Nil, **Conflict of Interest:** None declared.

AUTHOR INSTITUTION MAP FOR THIS ISSUE



Please note that not all the institutions may get mapped due to non-availability of requisite information in Google Map. For AIM of other issues, please check Archives/Back Issues page on the journal's website.